

Frequency of Hypertensive Retinopathy, on the basis of Imtiaz's Grading System, at Larkana Pakistan

Syed Imtiaz Ali Shah, Huda Fatima, Azizullah Jalbani, Shujaat Ali Shah, Partab Rai, Darikta Dargai Shaikh

Pak J Ophthalmol 2018, Vol. 34, No. 4

.....
See end of article for authors affiliations
.....

Correspondence to:
Syed Imtiaz Ali Shah
Professor of Ophthalmology
Chandka Medical College/SMBB
Medical University Larkana.
E-mail: syedimtiazalinaqvi@yahoo.com

Purpose: To determine the frequency of hypertensive retinopathy on the basis of "Imtiaz's Grading System of Hypertensive Retinopathy", at Larkana Pakistan.

Study Design: Case series study.

Place and Duration of Study: Department of Ophthalmology and Medical Unit 1 Chandka Medical College Hospital Larkana, Pakistan from January 2016 to January 2018.

Material and Methods: This study was conducted from January 2016 to January 2018 on 288 clinically diagnosed patients of hypertension by at least two senior consultants simultaneously and selected in accordance with inclusion and exclusion criteria. A standard proforma was filled in for every patient. Complete clinical examination including fundoscopy and blood pressure level was recorded. SPSS version 20 was used for data entry and analysis.

Results: Utilizing Imtiaz's Grading System of Hypertensive Retinopathy, out of the total 288 patients, 87 (30.21%) had hypertensive retinopathy. There were 39 (44.83%) male and 48 (55.17%) female patients. There were 51 (58.62%) patients who had Grade I hypertensive retinopathy, 19 (21.84%) patients had Grade II hypertensive retinopathy and 17 (19.54%) patients had Grade III hypertensive retinopathy. There were 83.9% patients presenting with headache, 35.6% complained of blurred vision, 17.2% patients complained of floaters, 8% had diplopia, 5.7% patients complained of pain in the eyes and 10.3% patients presented with transient visual loss (amaurosis fugax).

Conclusion: Early detection and management of hypertension and its systemic complications to prolong the life span of hypertensive patients, is possible if symptoms are given importance towards diagnosis of hypertension.

Keywords: Hypertensive retinopathy, Hypertension, Headache, Diplopia.

.....
Hypertensive retinopathy not only causes damage to eyesight but its presence is strongly associated with cardiovascular disease¹. The increasing incidence of hypertension in the global community i.e. at the start of twenty first

century more than a quarter of the world's population is suffering from hypertension². Other vital organs of the body involved include kidneys and central nervous system, the most common part of the human body being involved in hypertension is retina³.

Normal view of the retinal vessels visible on ophthalmoscopy is formed by the reflection from the interface between the blood column and vessel wall⁴. With persistently raised blood pressure leading to sclerosis and hyalinization of vessel walls, the appearance of retinal vessels changes first to red-brown (copper wiring) and then to complete sheathing (silver wiring) and focal areas of narrowing develop in them due to vascular spasm followed by fibrosis⁵. Sclerosis upon sustained hypertension may shorten or elongate the retinal arterioles which may consequently lead to deflection of the veins at the common sheath changing the course of the veins (Salus sign)⁶. The thickened wall of retinal arteriole in hypertension leads to compression of vein at the arteriovenous crossing resulting in dilated vein peripheral to crossing, arteriovenous nicking, known as the Gunn sign⁴. The rationale of the study was to introduce a new Grading System of Hypertensive Retinopathy which describes three grades of hypertensive retinopathy on the basis of retinal signs of hypertensive retinopathy and associated systemic symptoms⁷. This grading system was chosen for this study on the basis of the fact that it is based on both signs and symptoms contrary to other available Grading Systems of Hypertensive Retinopathy which are based on signs only^{8, 9,10,11,12}. The purpose of this study was to determine the frequency of hypertensive retinopathy on the basis of "Imtiaz's Grading System of Hypertensive Retinopathy" in this part of Pakistan for the first time.

MATERIAL AND METHODS

A total of 288 diagnosed patients of essential hypertension (with persistently raised blood pressure over 150/100 mmHg) presenting at the Department of Ophthalmology and Department of Medicine Unit-1, Chandka Medical College Hospital Larkana Pakistan from January 2016 to January 2018 were included in the study, after Ethical Approval from Ethical Review Committee of SMBB Medical University Larkana Pakistan. On duty residents/consultants of Department of Ophthalmology and Medicine Unit-1, Chandka Medical College Hospital Larkana were provided with standard proforma and instructed to record the symptomatic hypertensive patients on the basis of inclusion/exclusion criteria and report to Author No. 1 and 3 as a part of data collection

procedure. Patients below 20 years of age, with diabetes mellitus, with sickle-cell retinopathy, with retinal vasculitis and with hypertension due to secondary causes like renal hypertension and adrenal medulla tumors were excluded from the study. Complete clinical examination was performed on each patient including blood pressure monitoring, fundoscopy with direct and indirect ophthalmoscopes and with 90 D lens on slitlamp biomicroscope. A standard proforma was filled in for every patient; it included family history of hypertension, fundoscopic evidence of signs of hypertensive retinopathy and associated symptoms. Presence of Hypertension in first degree relatives was considered as positive family history. Sample size was calculated by using the formula
$$n = \frac{z^2 p (1-p)}{e^2}$$

Where 'n' is the sample size, 'z' is the confidence level, 'p' is the population proportion and 'e' is the margin of error. Sample size of 288 was calculated by keeping the confidence level of 95%, margin of error of 5.78 and assuming the population proportion to be 50%. Data was entered and analyzed in SPSS version 20 to assert the correlation of symptoms and signs in the relevant grades of hypertensive retinopathy by calculating the percentages of gender, hypertensive retinopathy, its various grades and symptoms among the patients under study.

RESULTS

We evaluated 288 patients of hypertension out of which 87 (30.21%) patients were found to have hypertensive retinopathy, among these patients 39 (44.83%) were males and 48 (55.17%) were females. Breakup of these patients in grades and presenting symptoms are shown in Table-1 & 2 and Figures 1. Utilizing Imtiaz's Grading System of Hypertensive Retinopathy, out of the total 87 patients, 51 (58.62%) had Grade I hypertensive retinopathy, 19 (21.84%) patients had Grade II hypertensive retinopathy and 17 (19.54%) patients had Grade III hypertensive retinopathy. The most common presenting complaint in patients was headache 73 patients (83.9%) followed by blurred vision in 31 patients (35.6%), floaters in 15 patients (17.2%), amaurosis fugax in 9 patients (10.3%), diplopia in 7 patients (8%) and eye pain in 5 patients (5.7%).

Table 1: Distribution of patients in various grades of retinopathy.

Symptoms	Grades of Hypertensive Retinopathy			Total (n=87)
	Grade I (n=51)	Grade II (n=19)	Grade III (n=17)	
Blurred vision	11	5	15	31
Headache	45	15	13	73
Diplopia	0	4	3	7
Floaters	0	12	3	15
Eye pain	0	0	5	5
Amaurosis fugax	0	0	9	9

Table 2: Gender Distribution.

		Distribution of Hypertensive Retinopathy		
		Hypertensive Patients without HR	Hypertensive Patients with HR	Total
Gender	Male	137	39	176
	Female	64	48	112
	Total	201	87	288

HR = Hypertensive Retinopathy

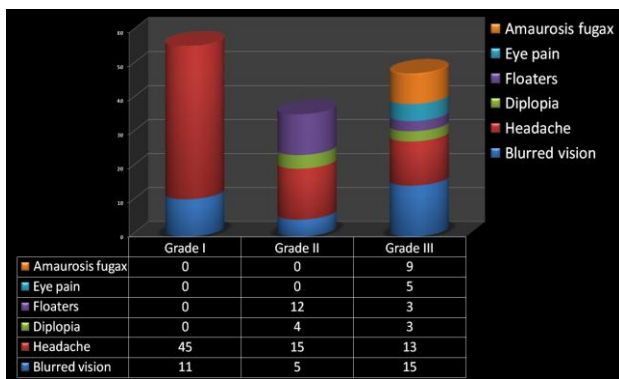


Fig. 1: Distribution of patients in various grades.

DISCUSSION

Retina is the only part of the human body where vasculature can be visualized noninvasively. Therefore state of vessels can be studied easily, adequately and at earliest in systemic disorders like hypertension and diabetes. Based on Imtiaz’s Grading System of Hypertensive Retinopathy, our study shows that most of the patients (71.46%) suffering from hypertension became symptomatic in the first two grades which is expected to coincide with less damage to the target organs in the body contrary to grade-3 which may reflect advanced target organ damage^{13,14}. Underestimation of the importance of classifying

hypertensive retinopathy is not justifiable as it not only guides the management of retinal problems but stays as a marker of vital organ damage. International Society of Hypertension and British Hypertension Society consider that Grade-3 and 4 of Keith, Wagener, Barker Grading coincides with presence of the target organ damage^{15,16}. Medical specialists have utilized hypertensive retinopathy to predict the morbidity and even the mortality related to hypertension¹⁷ therefore assessment of hypertensive retinopathy has a crucial place in management of patients with hypertension^{18, 19}. Researchers have shown favor for development of hypertensive retinopathy classification comprising of fewer grades like mild, moderate and malignant²⁰to facilitate easier clinical use. To our knowledge presently only Imtiaz’s Grading System of Hypertensive Retinopathy⁷ is based on both signs/symptoms and fewer grades (Three grades). **Imtiaz’s grading of Hypertensive Retinopathy** describes three grades of hypertensive retinopathy, **Grade 1**. Silver wiring of arterioles with AV nippings and headaches. **Grade 2**. As Grade 1 with flame shaped hemorrhages, soft exudates and floaters. **Grade 3**. As Grade 2 with papilledema and amaurosis fugax. According to our knowledge, there is one Grading system “Mitchell-Wong simplification of KWB system” that utilizes fewer grades (Three grades) but is based only on signs. Although this study is limited and a large study

is required to better explore the prevalence of hypertensive retinopathy in this part of Pakistan, the present study has opened the gate of understanding regarding picking up hypertensive retinopathy at relatively early stage on the basis of symptoms and has pointed out (30.21%) prevalence of hypertensive retinopathy in hypertensive population in upper parts of Sindh and adjacent Baluchistan.

CONCLUSION

The observations of our study reveals that most of the patients had mild to moderate degree of hypertensive retinopathy (in first two grades of Imtiaz's Grading System of Hypertensive Retinopathy, 71.46%) at the time of presentation and they attended the health facility due to symptoms like blurred vision, headache and floaters. Therefore, relatively early detection and management of hypertension and its systemic complications to prolong the life span of hypertensive patients, is possible if symptoms are given importance towards early detection and diagnosis of hypertension. On the basis of our study, we recommend that all symptomatic patients with raised blood pressure must undergo fundoscopy as a routine in all departments, to detect and manage hypertensive retinopathy and its associated complications either at the same health facility or by referral to appropriate place.

Author's affiliation

Prof. Syed Imtiaz Ali Shah
FCPS, Professor, Department of Ophthalmology
Chandka Medical College/SMBB Medical University
Larkana.

Dr. Huda Fatima
Trainee Registrar, Department of Ophthalmology
Chandka Medical College Larkana.

Dr. Azizullah Jalbani
Professor, Department of Medicine
Chandka Medical College/SMBB Medical University
Larkana.

Dr. Shujaat Ali Shah
Trainee Registrar, Department of Ophthalmology
Chandka Medical College Larkana.

Dr. Partab Rai
FCPS, Professor, Department of Ophthalmology
Chandka Medical College/SMBB Medical University
Larkana.

Dr. Darikta Dargai Shaikh
Associate Professor, Department of Ophthalmology
Chandka Medical College/SMBB Medical University
Larkana.

Role of Authors

Prof. Syed Imtiaz Ali Shah
Conceived and designed the research, assessed the cases, wrote the paper.

Dr. Huda Fatima
Collected the data, did the literature search, drafted the manuscript, assisted in writing the paper.

Dr. Azizullah Jalbani
Involved in data collection, analyzed the data, revised the manuscript.

Dr. Shujaat Ali Shah
Revised the original manuscript, reviewed the cases, analyzed the data and assisted in writing the paper.

Dr. Partab Rai
Revised the original manuscript, reviewed the cases.

Dr. Darikta Dargai Shaikh
Involved in data collection.

Disclaimer: None.

Conflict of Interest: None.

Source of Funding: None.

REFERENCES

1. **Wong TY, McIntosh R.** Hypertensive retinopathy signs as risk indicators of cardiovascular morbidity and mortality. *Br Med Bull.* 2005 Sept. 73-74: 57-70.
2. **Zampagione B, Pascale C, Marchisio M, et al.** Hypertensive urgencies and emergencies; prevalence and clinical presentation. *Hypertension*, 1996; 27: 44-147.
3. **Shubhangi V Dhadke, Vithal N Dhadke, Dhruv S Batra.** Clinical Profile of Hypertensive Emergencies in an Intensive Care Unit. *J Assoc Physici Ind.* 2017; 65: 18-22.
4. **Spencer WH.** An Atlas and Textbook (CD-ROM). *Systemic diseases with retinal involvement: vascular diseases.* Based on: *Ophthalmic Pathology.* WB Saunders Co; 1995.
5. **Wang S, Xu L, Jonas JB, Wang YS, Wang YX, You QS, et al.** Five-Year Incidence of Retinal Microvascular Abnormalities and Associations with Arterial Hypertension: The Beijing Eye Study 2001/2006. *Ophthalmol.* 2012; 119: 2592-9.

6. **Albert D, Jakobiec F, Christlieb RA.** Based on: Principles and Practice of Ophthalmology (CD-ROM). *Hypertension*. WB Saunders Co; 1993.
7. **Shah SIA et al.** Concise Ophthalmology Text & Atals. 5th ed. Param B (Pvt.) Ltd. 2018: 85-95.
8. **Wong TY, Mitchell P.** Hypertensive retinopathy. *N Engl J Med* 2004; 351: 2310- 2317.
9. **Scheie HG.** Evaluation of ophthalmoscopic changes of hypertension and arteriolar sclerosis. *AMA Arch Ophthalmol*. 1953; 49: 1170- 1238.
10. **Keith NM, Wagener HP, Barker NW.** Some different types of essential hypertension: their course and prognosis. *Am J Med Sci*. 1939; 197: 332-343.
11. **Chatterjee S, Chattopadhyay S, Hop e-Ross M, Lip PL.** Hypertension and the eye: changing perspectives. *J Hum Hypertens*. 2002; 16: 667-675.
12. **Ferdinand KC, Saunders E.** Hypertension-related morbidity and mortality in African Americans-why we need to do better. *J Clin Hypertens*. 2006; 8: 21-30.
13. **Noblat AC, Lopes MB, Lopes AA.** Race and hypertensive target-organ damage in patients from an university-affiliated outpatient care referral clinic in the city of Salvador. *Arq Bras Cardiol*. 2004; 82: 116-20, 111-5.
14. **Cheung CY, Ikram MK, Sabanayagam C, Wong TY.** Retinal micro-vasculature as a model to study the manifestations of hypertension. *Hypertens*. 2012; 60: 1094-103.
15. **Whitworth JA;** World Health Organization, International Society of Hypertension Writing Group. 2003 World Health Organization (WHO)/ International Society of Hypertension (ISH) statement on management of hypertension. *J Hypertens*. 2003; 21(1): 1983-92.
16. **Williams B, Poulter NR, Brown MJ, Davis M, McInnes GT, Potter JF, et al.** British Hypertension Society guidelines for hypertension management 2004 (BHS-IV): summary. *BMJ*. 2004, 328 (1): 634-40.
17. **Tso MO, Jampol LM.** Pathophysiology of hypertensive retinopathy. *Ophthalmology*, 1982; 89: 1132-1145.
18. **Mancia G, Fagard R, Narkiewicz K, et al.** ESH/ESC Guidelines for the Management of Arterial Hypertension: the Task Force for the management of arterial hypertension of the European Society of Hypertension (ESH) and of the European Society of Cardiology (ESC). *J Hypertens*. 2013; 31: 1281-357.
19. **Taylor J.** 2013 ESH/ESC guidelines for the management of arterial hypertension. *Eur Heart J*. 2013; 34: 2108-2109.
20. **Downie LE, Hodgson LAB, D'Sylva C, et al.** Hypertensive retinopathy: comparing the Keith-Wagener-Barker to a simplified classification. *J Hypertens*. 2013; 31: 960-65.